



Ipsilateral humeral neck and shaft fractures

Ipsilateralni prelom vrata i dijafize humerusa

Bin Zhu*, Ivan Micić†, Kyung-Chun Kim‡, Jin-Young Park§, Aashay Kekatpure||, Predrag Stojiljković†, In-Ho Jeon||

*Department of Hand Surgery, Ningbo No. 6 Hospital, Ningbo, Zhejiang, China;

†Clinic for Orthopaedic Surgery and Traumatology, Faculty of Medicine, University of Niš, Niš, Serbia; ‡Chungnam National University, Daejeon, Korea; §Konkuk University, Seoul, Korea, ||Asan Medical Center, Ulsan University, School of Medicine, Seoul, Korea

Abstract

Background/Aim. Fractures of the proximal humerus or shaft are common, however, ipsilateral neck and shaft humerus fracture is a rare phenomenon. This combination injury is challenging for orthopaedic surgeons because of its complex treatment options at present. The purpose of this study was to review a series of ipsilateral humeral neck and shaft fractures to study the fracture pattern, complications and treatment outcomes of each treatment options used. **Methods.** A total of six patients (four female and two male) with the average age of 42.8 years (range: 36–49 years) was collected and reviewed retrospectively. Two of them were treated with double plates and four with antegrade intramedullary nail. According to the Neer's classification, all proximal fractures were two-part surgical neck fractures. All humeral shaft fractures were located at the middle of one third. Five fractures were simple transverse (A3), one fragmented wedge fracture (B3). One patient had associated radial nerve palsy. **Results.** All surgical neck fractures except one united uneventfully in the average time span of 8.7 weeks. Four humeral shaft fractures healed in near anatomic alignment. The remaining two patients had the nonunion with no radiological signs of fracture healing. The average University of California, Los Angeles End-Results (UCLA) score was 23.1. On the contrary, the average American Shoulder and Elbow Surgeon's (ASES) score was 73.3. The patients treated with antegrade intramedullary nails presented 70.5 points. The ASES scores were 79 in the double plates group. **Conclusions.** Ipsilateral humeral shaft and neck fracture is extremely rare. Both antegrade intramedullary nailing and double plates result in healing of fractures. However the risk of complication is lower in the double plating group.

Key words:

humeral fractures; fractures, multiple; fracture fixation, intramedullary; bone plates; treatment outcome.

Apstrakt

Uvod/Cilj. Prelomi proksimalnog humerusa ili dijafize humerusa su vrlo česti prelomi, međutim, ipsilateralni prelom proksimalnog humerusa i dijafize je vrlo redak. Ova kombinacija preloma je izazov za ortopedске hirurge zbog složenih opcija lečenja. Cilj ove studije bio je da se prikaže serija ipsilateralnih preloma proksimalnog humerusa i dijafize, razmotre komplikacije i ishod dve različite metode hirurškog lečenja. **Metode.** Šest bolesnika (četiri žene i dva muškarca) prosečne starosti 42,8 godina (raspon 36–49 godina); analizirani su retrospektivno. Dva bolesnika lečena su duplim pločama, a četiri anterogradnim plasiranjem intramedularnog klina. Prema Nerovoj klasifikaciji, svi prelomi proksimalnog okrajka humerusa bili su dvodelni. Svi prelomi dijafize bili su locirani u srednjoj trećini, pet preloma bila su tipa A3, a jedan tipa B3, prema AO klasifikaciji. Jedan bolesnik imao je leziju radijalnog nerva. **Rezultati.** Svi prelomi proksimalnog okrajka (vrata) humerusa, sem jednog, zarasli su bez komplikacija za prosečno vreme od 8,7 nedelja. Četiri preloma dijafize humerusa zaraslo je u dobroj poziciji, dok kod dva preloma nije došlo do zarastanja (bez radioloških zarastanja). Prosečni *University of California, Los Angeles* (UCLA) skor bio je 23,1. Naprotiv, prosečan *American Shoulder and Elbow Surgeon's* (ASES) skor iznosio je 73,3. Bolesnici lečeni anterogradnim intramedularnim uklinjavanjem imali su prosečni ASES skor 70,5, dok je skor kod bolesnika lečenih duplom pločom iznosio 79. **Zaključak.** Ipsilateralni prelomi proksimalnog humerusa i dijafize vrlo su retki. Primenom anterogradne intramedularne fiksacije ili osteosinteze duplom pločom postiže se zarastanje preloma, međutim, rizik od komplikacija niži je kod ipsilateralnih preloma rešenih osteosintezom duplom pločom.

Ključne reči:

humerus, prelomi; prelomi, multipli; prelomi, intramedularna fiksacija; pločice za kost; lečenje, ishod.

Introduction

Fractures of the proximal humerus or shaft are common; however, simultaneous fracture of the ipsilateral humeral neck with shaft is an uncommon occurrence. This phenomenon has been seldom reported in the literature¹. Ipsilateral femoral neck and shaft fracture is well-reported, and this unique fracture is encountered in younger patients after high-energy trauma^{2,3}.

There has been no report on the fracture pattern, complications and surgical outcomes regarding ipsilateral humeral neck and shaft fracture in the literature, nor suggested fracture mechanism. This combination injury is challenging for orthopaedic surgeons because of its uncommon occurrence and there is a lack of consensus about surgical management of this complex trauma pattern. The goal of the treatment is fracture healing and avoiding potential complications such as avascular necrosis, nonunion or delayed union.

The aim of this study was to review a series of this rare ipsilateral humeral neck and shaft fractures, to study this fracture pattern in detail, to understand the treatment options used and highlight the potential complications.

Methods

Between January 1999 and December 2006, a total of six patients with ipsilateral humeral neck and shaft fractures were collected and reviewed. All medical notes and radiographs were reviewed retrospectively.

There were four female and two male patients, the average age of 42.8 years (range, 36–49 years). The right side was affected in three patients and this was the dominant arm in all the patients. Four of the patients were injured in road traffic accidents, and two by fall from a significant height. Four patients had other associated injuries: rib fractures of the same side in two patients, tibia and femur fractures in one, and anterior cruciate ligament injury in one.

Fracture classification

Proximal humerus fracture was classified based on both Neer's⁴ and Müller's⁵ AO Classification of Fractures. According to the Neer's classification, all fractures were included in two-part surgical neck fractures, except one which was one-part undisplaced fracture. There was no two-part tuberosity or three-, four-part fractures. Based on the Müller AO Classification of Fractures, there were two A32 (simple neck fracture with translation), one A31 (simple neck fracture with angulation), and the other three included in A2 (impacted metaphyseal fracture) without displacement (Figure 1).

Humeral shaft fractures were also classified based on the Müller AO Classification of Fractures. All humeral shaft fractures were in the middle of one third. Five fractures were included in simple transverse (A3), one in fragmented wedge fracture (B3). Of the five A3 fractures, three were spiral and two were oblique. One patient had associated radial nerve palsy (Table 1A).

Surgical technique

The average interval from the injury to surgery was 2.8 days (range: 1–5 days), and surgery was conducted as soon as the patients' overall medical condition was suitable.

Double plates technique

The deltopectoral approach was used for surgical neck fracture and the anterolateral Henry approach, splitting brachialis was used for shaft fracture fixation. One patient was treated with a T-shape dynamic compression plate for surgical neck fracture and the other one with a proximal humeral locking compression plate. The conventional 4.5 mm AO/ASIF limited contact dynamic compression plate (Synthes, Paloli, PA) was used for shaft fractures (Figure 2).

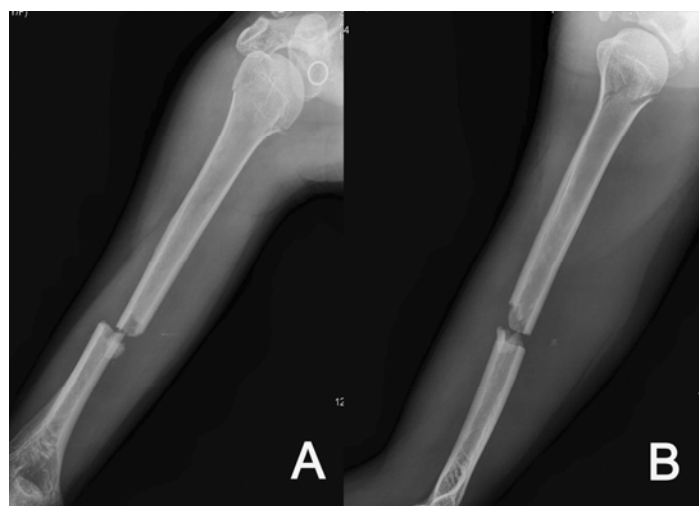

Fig. 1 – 47 year-old lady (case No 6) sustained multiple rib fractures and fractures of the right upper extremity. Proximal humeral neck fracture, initially not recognized, was identified. Non-displaced two-part surgical neck fracture, Müller AO Classification A2 (impacted metaphyseal fracture) was diagnosed for humeral neck fracture intraoperatively. Shaft fracture was classified as simple transverse fracture (AO Classification A31).

Table 1A

Details of the patients with ipsilateral humeral neck and shaft fracture

Case No	Age	Sex	Cause of injury	Associate injury	Diagnosis of the neck fracture	Side	Neck fracture (Neer)	Neck fracture (AO)	Shaft fracture (AO)	Op for neck	Op for shaft
1	49	F	RTA	None	Preop	L	2 part SN	A32	A32	CR/IF c AIN	OR/IF c AIN+cable
2	45	F	RTA	Radial n palsy	Intraop	L	2 part SN	A2	A31	CR/IF c AIN	OR/IF c AIN+cable
3	36	F	RTA	femur, tibia SI fx, MRF	Preop	R	2 part SN	A31	B	CR/IF c AIN +percu screw	CR/IF c AIN
4	40	M	Fall	None	Preop	R	2 part SN	A32	A31	OR/IF c Plate	OR/IF c Plate
5	40	M	RTA	ACL	Preop	L	2 part SN	A2	A32	CR/IF c AIN	CR/IF c AIN
6	47	F	Fall	MRF	Intraop	R	2 part SN	A2	A31	OR/IF c Plate	OR/IF c Plate

F – female; M – male; RTA – road traffic accident; Radial n palsy – radial nerve palsy; SI fx – sacroiliac fracture; MRF – multiple rib fractures; ACL – anterior cruciate ligament injury; Preop – preoperative; Intraop – intraoperative; L – left; R – right; SN – surgical neck; CR/IF c AIN – closed reduction and internal fixation with antegrade intramedullary nail; OR/IF c plate – open reduction and internal fixation with plate; percu screw – percutaneous screw fixation.

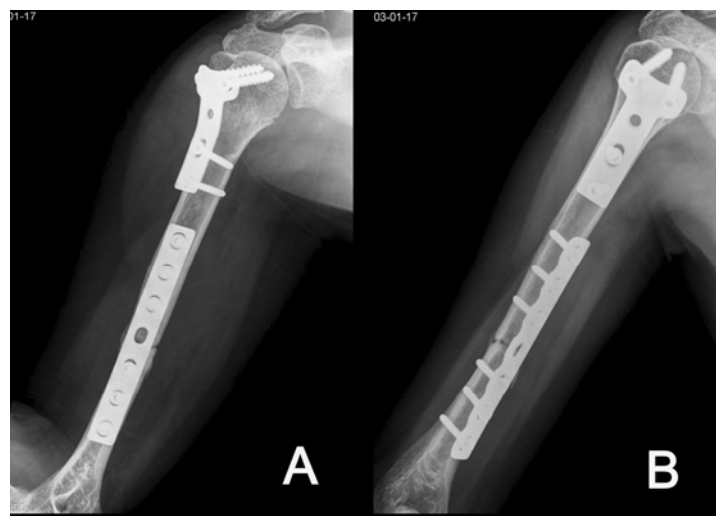


Fig. 2 – The previously described patient was treated with open reduction and internal fixation with double plates. Nine months after the operation, there was persistent fracture gap which required autogenous bone graft. However, there were no radiographic signs of avascular necrosis in the humeral head.

Antegrade intramedullary nail

Four of the patients were treated with antegrade type intramedullary nail. The anterolateral deltoid splitting approach between anterior and middle fibers of deltoid was used. After vertical incision in the *supraspinatus*, an entry portal was made at 2 cm posterior to the biceps groove. At least three proximal interlocking screws and two distal interlocking screws were used. Three of the patients were treated with Polaris intramedullary nail (Acumed, Beaverton, OR) (Figure 3). Two of them required additional circulate wiring for fixation of the spiral fracture of the shaft.

Functional outcome

Functional outcome of the shoulder was evaluated using the American Shoulder and Elbow Surgeons' (ASES) Score, and University of California, Los Angeles (UCLA) Score system^{6,7}.

Postoperative regimen

A functional brace with arm sling was applied after the operation in all patients. Active elbow and wrist range of motion exercise was allowed immediately after the operation. Pendulum and passive shoulder exercise started two weeks after the surgery, depending on the patients' tolerance. The active shoulder range of motion was only allowed after identification of fracture healing at radiographs.

Results

There were no open fractures identified. All the patients were followed-up for the mean of 35.6 (range, 12–60) months postoperatively.

Surgical neck fracture was not initially appreciated in two of the patients (cases 2 and 6), because of inadequate preoperative radiographs; thus the diagnosis was humeral shaft fracture preoperatively. During the operation for humeral

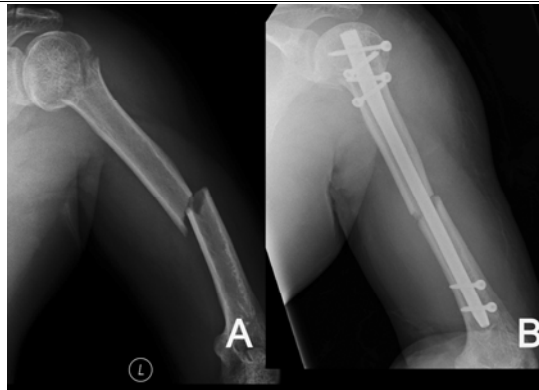

Fig. 3 –A 40-year-old man (case No. 5) sustained fracture after road traffic accident: **A)** Plain radiographs showed ipsilateral humeral neck and shaft fractures; **B)** The patient was treated with antegrade intramedullary nail Polaris (Acumed, Beaverton, OR) and postoperative radiographs presented 3 mm gap between the fracture fragments. The patient developed shaft nonunion which required autogenous bone graft.

ral shaft fixation, they were identified and diagnosed with AO type A2 (impacted metaphyseal fracture).

Surgical neck fracture outcome of treatment

All surgical neck fractures except one were united uneventfully on the average of 8.7 (range, 8–12) weeks. There was one nonunion in displaced surgical neck fracture (Müller AO Classification A32), which was treated initially with antegrade intramedullary nail. Nonunion was identified three months after the operation with re-displacement of a fracture fragment and screw loosening. Revision surgery was performed with a proximal humeral locking compression plate and autogenous bone graft, which resulted in union three months postoperatively (Figure 4).

Plain radiographs review until the final follow-up showed no patients with signs of avascular necrosis of the humeral head; none of the patients showed localized osteopenia, sclerosis, subchondral fracture, depression or flattening of head and fragmentation.

Humeral shaft fracture outcome of treatment

Four fractures healed in near anatomic alignment without significant shortening (1 cm or less) or angular deformity (over 10 degrees). The remaining two patients resulted in nonunion with no signs of fracture healing and persistent fracture gap in plain radiographs, both presented simple transverse fracture at initial examination (Müller AO Classification A3). These two patients required autogenous bone graft for bone union only. The average time to union was 12 weeks (range, 10–14 weeks) for shaft fractures. When the fracture healed the time for union was found to be similar in the double plate and nailing groups.

Functional outcome of the shoulder

The average UCLA score was 23.1 (range, 18–29). There were two good results, while four were poor (Table 1B).

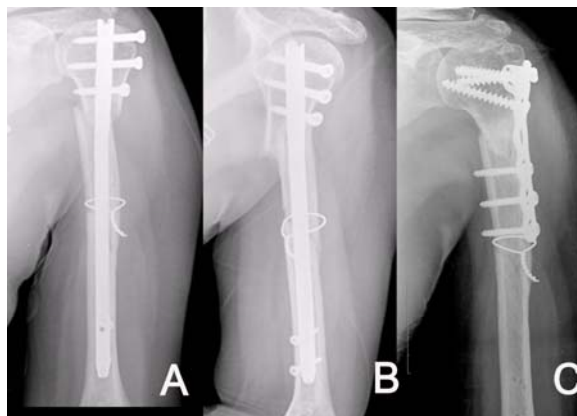


Fig. 4 – A 49-year-old lady (case No. 1) sustained fracture after road traffic accident: **A)** Plain radiographs showed ipsilateral humeral neck (two part surgical neck fracture, Müller AO Classification A32) and shaft fracture (Müller AO Classification A32). This was initially treated with antegrade intramedullary nail; **B)** persistent fracture gap seen was developed at 3 months after the operation with re-displacement of fracture fragment and screw loosening; **C)** Revision surgery was performed with proximal humeral locking compression plate and autogenous bone graft, which resulted in union three months after the revision surgery.

Table 1B

Details of the patients with ipsilateral humeral neck and shaft fracture									
Case No	Age	Sex	Union time for neck (weeks)	Union time for shaft (months)	Complications → subsequent revision surgery	UCLA score	ASES score	Flexion of Shoulder	Follow up (months)
1	49	F	Nonunion	3	Nonunion of the neck → Plate/BG	21	77	140°	28
2	45	F	12	3		18	60	140°	12
3	36	F	8	3	Flexible rod protrusion → implant removal	29	85	160°	28
4	40	M	12	3		22	73	160°	60
5	40	M	13	Nonunion	Nonunion of the shaft → BG	20	60	150°	38
6	47	F	8	10	delayed union of the shaft	29	85	160°	48

F – female; M – male; BG – bone graft; UCLA score – University of California, Los Angeles End-Result Score system; ASES – the American Shoulder and Elbow Surgeons'.

One patient with revision surgery for nonunion of neck fracture and another one with radial nerve palsy resulted in a poor functional result. One patient complained shoulder pain and motion limitation after antegrade nailing, because of protrusion of flexible intramedullary nail over the greater tuberosity. The symptoms were resolved with removal of the nail after fracture healing. The overall poor results were present in the patients who had revision surgery or delayed union or associated neurologic impairment in the same extremity.

Complications

There were no complications related to surgery, such as deep infection or neurovascular injuries. Two patients with nonunion (one in the humeral neck and the other one in the humeral shaft) from the antegrade intramedullary nail group and one nonunion from the double plates group underwent the additional autogenous bone graft procedure.

Discussion

Ipsilateral humeral shaft and neck fracture is rare, and has been paid less attention in the literature compared to ipsilateral femoral neck and shaft fracture. The reported incidence of ipsilateral femoral neck and shaft fracture ranged from 2.5% to 6% of all femoral shaft fractures². It is about 0.5% in our series for the last seven years.

Ipsilateral humeral neck and shaft fracture occur in the relatively young patients (the average age, 42) and they were the victims of high-energy injuries (four sustained their fracture after road traffic accident and two from a fall). However, none of these patients presented ipsilateral elbow or wrist injuries, although knee injuries are comparatively common in ipsilateral femoral neck and shaft fracture⁸.

In this series, three out of six neck fractures presented linear or minimally displaced surgical neck fractures classified as type A2, two-part surgical neck fracture. There were no two-part tuberosity fractures or three/four-part fractures of

the humeral neck in this series. Shaft fractures were mostly simple. Spiral fractures were more common than oblique or transverse pattern.

The femoral neck fracture is often missed and some authors recommended preoperative CT scan in high risk patients⁹. In this series, two neck fractures were identified intraoperatively, which were missed due to inadequate preoperative film. None of the patients presented associated glenoid or scapular fractures.

Numerous surgical treatment options are available for the treatment of humeral neck and shaft fracture, such as non-operative treatment, internal and external fixation, shoulder arthroplasty, intramedullary nail, and minimally invasive percutaneous osteosynthesis¹⁰⁻¹². However, only two techniques of intramedullary nail and plate fixation were used for ipsilateral humeral neck and shaft fracture^{2, 3, 8}. In this series, four patients were treated with reconstruction type antegrade intramedullary nailing using proximal interlocking screws for surgical neck fracture fixation. The other two had double plate fixation. In this series, we found a less chance of nonunion in the plate fixation group. In addition, the risk of shoulder stiffness related to surgical violation of rotator cuff violation was another concern in the patients treated with antegrade intramedullary nailing.

We had two patients with nonunion in humeral shaft fracture after antegrade intramedullary nailing, and both required additional bone graft for achievement of union. Previous studies showed that intramedullary nailing is associated with an increased risk of shoulder impingement, with the related increase in restriction of shoulder movement and the need to remove it, and is associated with the increased risk of the delayed healing rate^{13, 14}. However, in our study we found that the reconstruction type antegrade nailing for ipsilateral humeral neck and shaft fracture has a potential risk of nonunion in shaft fracture (two patients out of four had nonunion).

Complication such as avascular necrosis of the head was not observed in this series. There was no fracture dislocation in the shoulder and none of the neck fractures were identified late after the operation.

The limitation of this study is a small number of patients, retrospective review and no controlled study, which makes direct comparison of the two groups difficult. It also includes the inherent disadvantage of retrospective study, because there were no distinct indications of each different modes of fixation. However, considering the rarity of this injury, this series can provide valuable information to predict the prognosis to treating doctors who might encounter this complicated injury.

Conclusion

This was the first report of ipsilateral neck and shaft fracture, which delineated that concomitant neck fractures

are usually undisplaced or minimally displaced and shaft fractures are usually unstable. Considering the fact that there is no evidence-based medicine regarding optimal management of these combinations, it is useful to know that both antegrade intramedullary nailing and double plates produced reliable outcome for the treatment of this combination injury, but the risk of complication was lower in the double plating group.

Acknowledgement

This paper is part of the Project III 41017 and 175102, funded by the Ministry of Education, Science and Technological Development of the Republic of Serbia.

R E F E R E N C E S

1. Chun JM, Pawaskar A, Jeon IH. Fracture dislocation of the proximal humerus with ipsilateral shaft fracture: a report of two cases. *Acta Orthop Traumatol Turc* 2013; 47(5): 370–5.
2. Swiontkowski MF. Ipsilateral femoral shaft and hip fractures. *Orthop Clin North Am* 1987; 18(1): 73–84.
3. Watson J, Moed BR. Ipsilateral femoral neck and shaft fractures: complications and their treatment. *Clin Orthop Relat Res* 2002; 399: 78–86.
4. Neer CS. Displaced proximal humeral fractures. I. Classification and evaluation. *J Bone Joint Surg Am* 1970; 52(6): 1077–89.
5. Muller ME, Nazarian S, Koch P, Schatzker J. *The Comprehensive Classification of Fractures of Long Bones*. 1st ed. Berlin, Heidelberg, New York: Springer-Verlag 1990.
6. Richards RR, An KN, Bighani LU, Friedman RJ, Gartsman GM, Gristina AG, et al. A standardized method for the assessment of shoulder function. *J Shoulder Elbow Surg* 1994; 3(6): 347–52.
7. Ellman H, Hunker G, Bayer M. Repair of the rotator cuff. End-result study of factors influencing reconstruction. *J Bone Joint Surg Am* 1986; 68(8): 1136–44.
8. Albo A. Concurrent ipsilateral fractures of the hip and femoral shaft: A meta-analysis of 659 cases. *Acta Orthop Scand* 1996; 67(1): 19–28.
9. Yang KH, Han DY, Park HW, Kang HJ, Park JH. Fracture of the ipsilateral neck of the femur in shaft nailing. The role of CT in diagnosis. *J Bone Joint Surg Br* 1998; 80(4): 673–8.
10. Jordan RW, Modi CS. A review of management options for proximal humeral fractures. *Open Orthop J* 2014; 8: 148–56.
11. Carroll EA, Schweppe M, Langfitt M, Miller AN, Halvorson JJ. Management of humeral shaft fractures. *J Am Acad Orthop Surg* 2012; 20(7): 423–33.
12. Sharma V, Sharma S, Awasthi B. Long angular stable plates: A solution for complex fractures of humerus. *J Orthop Traumatol Rehabil* 2015; 8: 35–8.
13. Lin GD, Zhang QG, Ou LS, Zhou L, Fei J, Chen HW, et al. Meta-analysis of the outcomes of intramedullary nailing and plate fixation of humeral shaft fractures. *Int J Surg* 2013; 11(9): 864–8.
14. Kurup H, Hossain M, Andrew JG. Dynamic compression plating versus locked intramedullary nailing for humeral shaft fractures in adults. *Cochrane Database Syst Rev* 2011; (6): CD005959.

Received on September 2, 2014.

Revised on October 07, 2015.

Accepted on October 19, 2015.

Online First July, 2016.